

Neuroprotective effect of Coenzyme Q10 on ischemic hemisphere in aged mice with mutations in the amyloid precursor protein

Geng Li^{a,*}, Liangyu Zou^b, Clifford R. Jack Jr.^c, Yihong Yang^d, Edward S. Yang^a

^a Jockey Club MRI Center, Faculty of Medicine, The University of Hong Kong, Room 204, Chow Yei Ching Bldg., Pokfulam Road, Hong Kong, China

^b Department of Neurology, The First Affiliated Hospital, Harbin Medical University, PR China

^c Department of Diagnostic Radiology, Mayo Clinic and Foundation, 200 First Street SW, Rochester, MN 55905, USA

^d Neuroimaging Research Branch, National Institute on Drug Abuse, National Institutes of Health, 5500 Nathan Shock Drive, Building C, Baltimore, MD 21224, USA

Received 14 November 2005; received in revised form 11 April 2006; accepted 3 May 2006

Available online 30 June 2006

Abstract

This study was designed to test whether Coenzyme Q10 (CoQ10) supplementation has neuroprotective effect in aged, double-transgenic amyloid precursor protein (APP)/presenilin 1 (PS1), single transgenic APP and PS1 mice exposed to ischemic injury of the brain. Forty-eight mice (12 each of APP/PS1, APP, PS1 and wild-type) were studied. Half of each genotype groups ($n=6$ per group) was treated with CoQ10 (1200 mg/kg/day) after ischemic injury and the other half with placebo. Magnetic resonance (MR) images were used to measure the volume of induced infarction (IFV), as well as the volume of the hemispheres and hippocampi. Significantly greater volumes of infarction and lesser volumes of hemisphere/hippocampus on the ischemic side were observed in APP/PS1 and APP mice than in PS1 and wild-type mice. This is consistent with amplification of the effect of ischemia in APP carriers. After 28 days of CoQ10 treatment, APP/PS1 or APP mutations have smaller infarct volumes, while the volumes of hemisphere and hippocampus on the infarcted side were larger than those treated with placebo. No differences between CoQ10- and placebo-treated groups in volumes of infarct, hemisphere and hippocampus were observed in PS1 and wild-type mice. We conclude that CoQ10 has a protective effect on the brain from infarction and atrophy induced by ischemic injury in aged and susceptible transgenic mice.

© 2006 Elsevier Inc. All rights reserved.

Keywords: APP/PS1 double transgenic mice; Antioxidant; Stroke; Alzheimer's disease; Cerebral infarction

1. Introduction

Alzheimer's disease (AD) and ischemic cerebrovascular disease are the two most prevalent causes of dementia in the elderly [10,15,27]. Recent basic and clinical investigations demonstrate that AD and cerebrovascular disease, traditionally considered two independent neurological disorders, may interact in an additive manner [16]. In clinical studies, the presence of ischemic lesions aggravates the cognitive deficits in patients with AD pathology [9,37,43]. In AD patients, the extent of AD pathology at post-mortem is increased if ischemic stroke coexists [9]. Elderly subjects are more likely

to have been demented in life if both AD pathology and ischemic cerebrovascular disease are present at autopsy than if either pathology is found in isolation [10,12,15,18,19,27]. The theme of amplification of the effects of stroke in AD has been extended to animal models [2,6]. Zhang et al. [44] showed that transgenic mice with overexpressed APP are more susceptible to ischemic brain damage caused by middle cerebral artery occlusion (MCAO). Several studies suggest that both AD and stroke cause tissue damage by the same mechanism: oxidative stress [5,20,25,30,40,41].

Several investigators have identified a deficiency in complex IV, cytochrome *c* oxidase (COX) of the mitochondrial electron transport chain in AD patients and reduced activity of complexes I and III in ischemic conditions [1,26,40]. Coenzyme Q10 (CoQ10) is an essential cofactor produced

* Corresponding author. Tel.: +852 2293 0305; fax: +852 2540 6215.

E-mail address: ligeng@eee.hku.hk (G. Li).

endogenously and provided in the food chain. As the electron acceptor for mitochondrial complexes I and II, it plays an essential role in cellular energy production as an electron and proton carrier [8]. Complex I or II dysfunctions were found in neurological disorders such as Parkinson's disease and Huntington's disease [35]. Shults et al. reported a correlation between mitochondrial CoQ10 level and the biological activity of complexes I–IV [35]. CoQ10 supplementation is known to have a neuroprotective effect in neurodegenerative diseases, such as Parkinson's and Huntington's disease [34,36]. For example, in a recent clinical study Parkinson's disease patients who were given the highest dose of CoQ10 showed the greatest clinical benefits [33]. Oral CoQ10 supplementation increases brain mitochondrial concentration and exerts neuroprotective effects [24,29]. A neuroprotective effect of CoQ10 has been found in various animal models of stroke and this has been attributed to its role as a potent antioxidant and an oxygen-derived free radical scavenger [13,28,39]. This finding has not been universally replicated, however, as Li et al. found that immediate treatment with CoQ10 via intraperitoneal injection did not prevent neuronal injuries following global or focal ischemia [22]. Mitochondrial abnormalities have been found in human AD patients, and a therapeutic effect of CoQ10 has been reported in these patients [36]. Results have been mixed however; for example, de Bustos and coworkers found no relationship between serum levels of CoQ10 and the risk of either AD or vascular dementia [7,11,36].

In this study, we tested the neuroprotective effect of CoQ10 supplementation against experimental stroke in transgenic Alzheimer's mice. APP/PS1, APP, and PS1 transgenic mice, as well as wild-type mice were treated with a high dose of CoQ10 for 28 days following experimentally induced ischemic stroke. Treated and placebo animals were compared by quantitative post-mortem magnetic resonance imaging (MRI). Transgenic and wild-type mice were used in order to test that the destructive effects of stroke could be amplified in transgenic animals as described by Zhang et al. [44].

2. Materials and methods

2.1. Transgenic mice

All experiments were conducted according to institutional guidelines using a protocol approved by the Committee on the Use of Live Animals in Teaching and Research at the University of Hong Kong. Transgenic mice with a mixed background (C3H/HeJ/C57BL/A2G) co-expressing mutant human PS1-Leu235Pro and APP-swe were crossed to generate four strains: APP/PS1, APP, PS1 and wild-type. Forty-eight 18-month-old male (25–30 g) APP/PS1, APP, PS1 and wild-type mice (12 mice for each genotype) were determined using a standard protocol for the polymerase chain reaction (PCR).

2.2. Photo-thrombotic induction of cerebral ischemia

Mice were anesthetized with a 2:1 mixture of 10% Ketamine at a dosage of 150 mg/kg and 2% Xylazine (Alfasan, Woerden-Holland). The skull was exposed at the dorsal aspect of the head and bregma and lambda points were identified. One milligram (0.1 ml) of Rose Bengal (Aldrich) dissolved in sterile saline at a concentration of 10 mg/ml was injected intravenously 1 min before illumination. The brains were then illuminated with cold white light through the intact skull for 15 min at 2.0 mm posterior and 3.0 mm lateral to bregma on the left side using a fiber optic bundle (Intralux 150 H, Volpi, Zurich, Switzerland) and a halogen bulb (15 V, 150 W Xenophot HLX64634 EFR, Osram, Germany). Afterwards, the skin was sutured and the mice were allowed to recover [32].

2.3. Treatment

In each of the four genotype groups, half ($n = 6$) of the mice (the placebo group) were fed standard pelleted mouse chow only (Purina Test Diets, Richmond, IN). The treated mice ($n = 6$ per genotype) were fed the same mouse chow diet supplemented with CoQ10 (1200 mg/kg/day, Tishcon/Gel-Tec) for 28 days following stroke induction. The amount of food intake per mouse was 5–6 gm/day, with no significant difference between treated and untreated mice. During treatment, the food consumed per gram of mouse weight was stable.

2.4. Brain preparation

Twenty-eight days after inducing the stroke, mice were deeply anaesthetized and perfused through the left cardiac ventricle with phosphate-buffered saline (PBS) (pH 7.4), followed by 4% paraformaldehyde in PBS. The brain was then carefully removed and soaked in 4% paraformaldehyde at room temperature for 40–60 days, long enough for complete fixation process [4,21]. Each brain was positioned at the center of a plastic tube filled with Fomblin (Solvay Solexis, Inc. NJ, USA) and tightly sealed for MR measurements.

2.5. MRI evaluation

MRI was performed on a Philips Achiva 3 T whole-body MRI at the Jockey Club MRI Centre, Hong Kong with a transmit/receive wrist coil. To optimize contrast between grey and white matter for morphometry, we used a high-resolution three-dimensional (3D) turbo spin-echo (TSE) T1-weighted sequence. Parameters were repetition time (TR) = 500 ms, echo time (TE) = 14 ms, flip angle = 90°, water fat shift (WFS)/bandwidth (BW) = 3.098 pix/140.2 Hz, field-of-view (FOV) = 8 cm × 8 cm, matrix size = 400 × 400 producing an in-plane voxel size of 0.20 mm × 0.20 mm, TSE factor = 3, slice thickness in the through-plane direction = 0.5 mm without slice gap, and number of signal averages (NSA) = 70. To achieve image contrast between infarct and normal brain

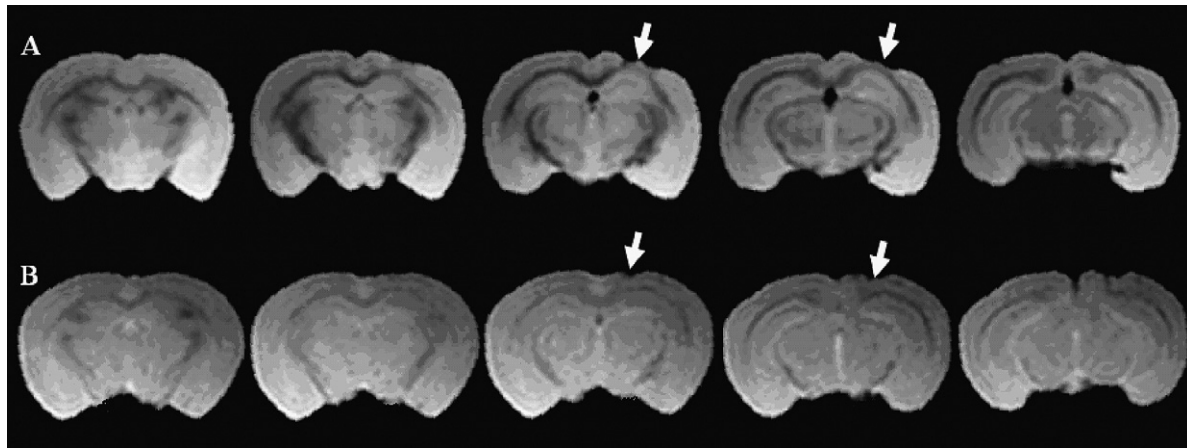


Fig. 1. 3D-TSE T1-weighted coronal MRI slices of brains from APP/PS1 transgenic mice in placebo (A) and CoQ10 treatment (B) groups. Arrows indicate regions of infarction. Individual sections are in caudal to cranial order from left to right.

tissue, a high-resolution 3D-TSE T2-weighted brain image was acquired. The imaging parameters were: TR = 2000 ms, TE = 26 ms, WFS/BW = 3.029 pix/143.4 Hz, FOV = 10 cm × 10 cm, matrix size = 400 × 400 producing an in-plane voxel size of 0.25 mm × 0.25 mm, slice thickness = 0.5 mm without slice gap, and NSA = 70. Infarct volume (IFV) was measured from the high-resolution 3D-TSE T2-weighted images. The volume of each infarct was delineated with manual region of interest (ROI) tracing using image-processing software (Analyze 5.0; AnalyzeDirect, USA). For the calculation of hemispheric and hippocampal volumes, ROIs were manually drawn on two consecutive slices of the 3D-TSE T1-weighted images using Analyze. In order to correct for normal size differences between animals, volume results were expressed as a ratio relative to the unaffected hemisphere [3,14].

2.6. Statistical analysis

Numerical results are presented as mean ± standard error (S.E.). Statistical comparisons of IFV, LHV, RHV, LHSV and RHSV data were compared by Tukey Multiple Comparison in a one-way ANOVA test using SPSS 13.0 (SPSS Inc. Chicago, USA). The level of significance was set at $p < 0.05$.

3. Results

3.1. Effect of CoQ10 on relative cerebral infarct volume (IFV) in APP/PS1, APP, PS1 and wild-type mice

Fig. 1 shows coronal MRI slices of brain specimens of APP/PS1 transgenic mice without CoQ10 treatment (A) and with CoQ10 treatment (B). Measurement of the volume of the stroke divided by the volume of the non-infarcted hemisphere (IFV) showed that, for each of the four genotypes, relative IFV was larger in the placebo than the treated group (Fig. 2). The treatment effect was significant in APP/PS1

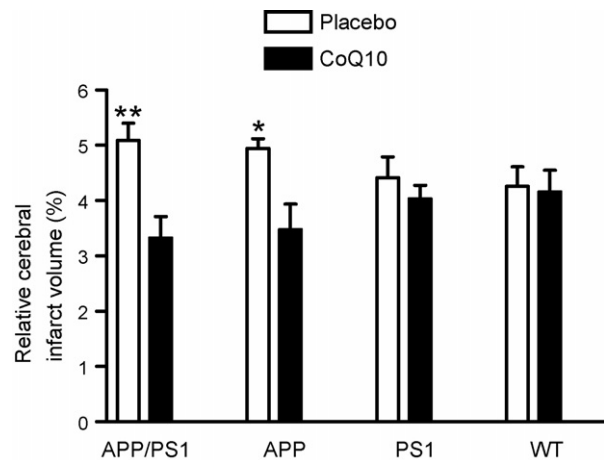


Fig. 2. Effect of 28 days treatment with CoQ10 on cerebral infarct volume (IFV) in APP/PS1, APP, PS1 and wild-type mice ($n = 6$ in each group). Data are expressed as lesion volume divided by the unaffected contralateral hemisphere volume with four pair-wise comparisons: (1) placebo vs. CoQ10 in APP/PS1; (2) placebo vs. CoQ10 in APP; (3) placebo vs. CoQ10 in PS1; and (4) placebo vs. CoQ10 in wild-type. **Comparison with placebo, $p < 0.01$; *comparison with placebo, $p < 0.05$. Error bars indicate standard error (S.E.).

($p < 0.01$) and APP ($p < 0.05$) but not in PS1 and wild-type mice.

3.2. Effect of CoQ10 on ratio of hemisphere volume (HSV)

Values for the volume of the infarcted hemisphere divided by the volume of the non-infarcted hemisphere (HSV) showed no differences in treated mice among the four different genotype groups (Fig. 3). The HSV was significantly smaller (indicating greater stroke-induced atrophy in the infarcted hemisphere) in placebo than CoQ10-treated mice in both APP/PS1 ($p < 0.01$) and APP ($p < 0.05$) transgenic mice, indicating a protective effect of CoQ10. There was no significant difference in the ratio of HSV between placebo

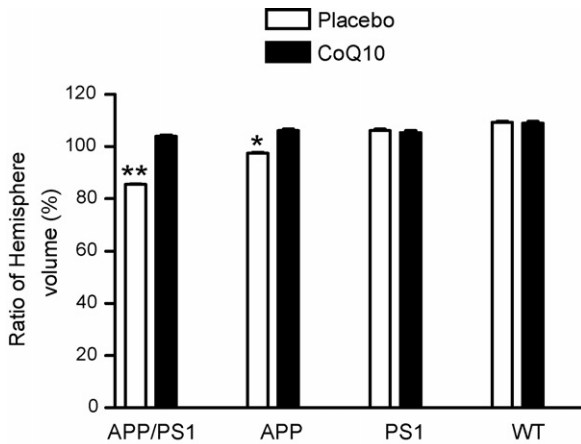


Fig. 3. Effect of CoQ10 on ratio of hemisphere volume (HSV) in APP/PS1, APP, PS1 and wild-type mice. Data are expressed as volume of the ischemic hemisphere divided by the volume of the non-ischemic side with four pairwise comparisons: (1) placebo vs. CoQ10 in APP/PS1; (2) placebo vs. CoQ10 in APP; (3) placebo vs. CoQ10 in PS1; and (4) placebo vs. CoQ10 in wild type or bars indicate standard error (S.E.). ** Comparison with placebo, $p < 0.01$; * comparison with placebo, $p < 0.05$. Error bars indicate standard error (S.E.).

and CoQ10 groups in PS1 transgenic mice and wild type-mice ($p > 0.05$).

3.3. Effect of CoQ10 on relative hippocampal volume (HV) in APP/PS1, APP, PS1 and wild-type mice

Normalized hippocampal volume was calculated by dividing hippocampal volumes by the volume of the non-ischemic hemisphere (Fig. 4). In the treated groups, this ratio was significantly larger in both APP/PS1 ($n = 12$, 6 in each group, $p < 0.01$) and APP ($n = 12$, 6 in each group, $p < 0.05$) transgenic mice than that in the placebo groups. This indicates a protective effect of CoQ10 on the volume of the hippocampus on the infarcted side relative to placebo. However, there was no significant difference between the placebo and treated groups in PS1 transgenic mice ($n = 12$, 6 in each group, $p > 0.05$) or wild-type mice ($n = 12$, 6 in each group, $p > 0.05$). Furthermore, there was no significant difference in normalized HV on the intact side between the placebo and treated groups in any of the mouse strains ($n = 48$, 6 in each group, $p > 0.05$).

4. Discussion

CoQ10 is known to have a neuroprotective effect in Parkinson's disease and Huntington's disease [11,34,35,38]. Nevertheless, few studies have investigated its effects on Alzheimer's disease and stroke. In the present study, we found that: (1) 4 weeks of CoQ10 treatment reduced IFV in APP/PS1 and APP transgenic mice, but had no effect on IFV in PS1 transgenic mice and wild-type mice; (2) CoQ10 treatment preserved HSV (ischemic hemisphere volume versus

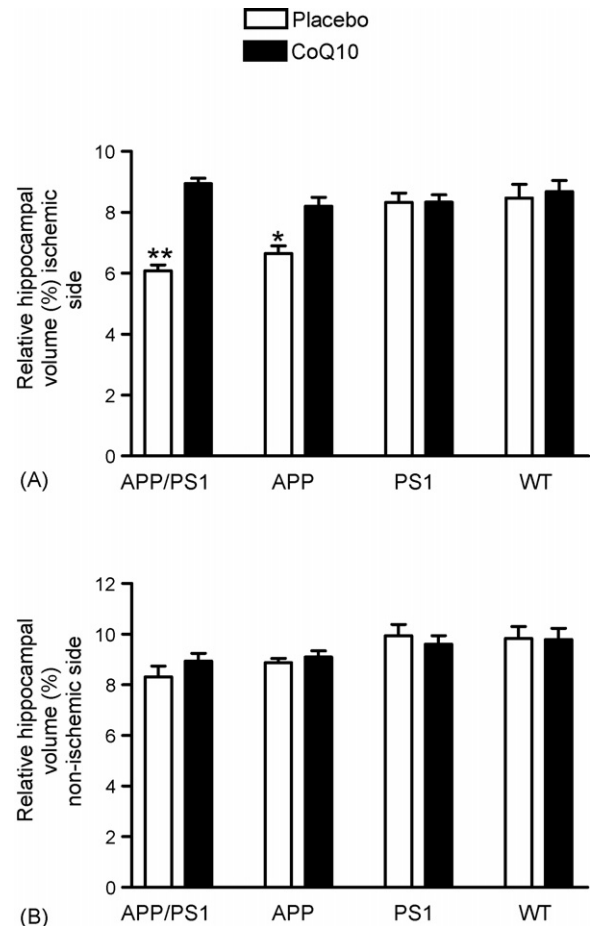


Fig. 4. Effect of CoQ10 on relative volume of hippocampus in APP/PS1, APP, PS1 and wild-type mice. Data are expressed as volume of hippocampus divided by the volume of the non-ischemic hemisphere. Comparisons are between CoQ10 treatment vs. placebo in both ischemic (A) and non-ischemic sides (B). ** Comparison with placebo, $p < 0.01$; * comparison with placebo, $p < 0.05$. Error bars indicate standard error (S.E.).

non-ischemic side) in APP/PS1 and APP transgenic mice, but not in PS1 transgenic mice and wild-type mice; (3) CoQ10 treatment preserved HV (hippocampal volume on the ischemic side versus non-ischemic side) in APP/PS1 and APP transgenic mice, but not in PS1 transgenic mice and wild-type mice.

Transgenes related to Alzheimer's disease have been reported to increase susceptibility to cerebral ischemia; Zhang et al. [44] reported that the infarct volume caused by MCAO was greater in APP transgenic mice, than in wild-type mice [44]. Our results from APP and APP/PS1 transgenic mice confirm those of Zhang et al. [44]. Our methods differed from those of Zhang et al. [44] in that we used photo-thrombosis to induce cerebral ischemia. Photo-thrombosis causes cerebral infarct by local activation of the photosensitive dye and subsequent free radical formation, which can disturb endothelium and activate platelet aggregation and coagulation cascades [42]. Compared with MCAO, photo-thrombotic stroke produces a more localized area of infarction [42]. In our experiments, APP/PS1 mice exhibited

greater sensitivity to ischemic injury than APP mice, while PS1 and wild type mice exhibited a similar insensitivity to ischemic injury relative to APP carriers. A possible explanation is linked to the fact that APP/PS1 mice deposit plaques at a significantly greater rate than that in APP mice, while PS1 and non-transgenic mice do not deposit plaques [6]. By 18 months, the plaque load in APP/PS1 is quite dense while the load in APP mice is modest. Further, the putative link between A β production and susceptibility to ischemic damage is that A β can induce free radical formation [31]. A β deposition is accompanied by proportional molecular evidence of mitochondrial and oxidative stress in APP/PS1 mice [10]. We noted (Fig. 2) that among the different mouse strains studied, stroke volume increased in proportion to expected A β load: APP/PS1 > APP > PS1 = wild type. These results support the notion of an additive and dose dependent interaction between A β production and the destructive effects of stroke. We also noted a greater protective effect of CoQ10 among mouse strains studied in proportion to expected A β production: APP/PS1 > APP > PS1 = wild type. Based on the link between rate of A β production and induced oxidative stress, these results would be expected if CoQ10 was indeed exerting a protective effect via reduction of oxidative stress.

Differences in HSV between the two sides of the brain and the ratio of HSV represent hemispheric atrophy associated with ischemic stroke. In the present study, the HSV ratio in the placebo group was smaller (greater atrophy) than that in the treated group in both APP/PS1 and APP mice. In a manner analogous to that observed for stroke volume, the difference in HSV between treated and untreated mice increased among the different mouse strains studied in proportion to expected A β load: APP/PS1 > APP > PS1 = wild type. Hippocampal atrophy is a widely recognized morphological characteristic of Alzheimer's disease in humans [17,23]. In the present study, since the infarction did not directly involve the hippocampi, we speculate that stroke-induced hippocampal atrophy is a reflection of neuronal deafferentation of the hippocampus ipsilateral to the stroke. CoQ10 preserved hippocampal volume on the ischemic side relative to the uninvolved contra lateral hemisphere again in a manner that suggests graded dependence on A β load: APP/PS1 > APP > PS1 = wild type.

In summary, this study suggests that susceptibility to ischemic injury is enhanced in proportion to capacity for A β production. Our results also suggest a neuroprotective effect of CoQ10 treatment in transgenic animals that are particularly susceptible to ischemic insult due to A β over production. This is consistent with the ability of CoQ10, a free radical scavenger, to exert a neuroprotective effect through reduction of oxidative stress [24,29].

Acknowledgements

This study was supported by grants from Rejuvenis and The Hong Kong Jockey Club Charities Trust.

References

- [1] Allen KL, Almeida A, Bates TE, Clark JB. Changes of respiratory chain activity in mitochondrial and synaptosomal fractions isolated from the gerbil brain after graded ischaemia. *J Neurochem* 1995;64(5):2222–9.
- [2] Ancolio K, Marambaud P, Dauch P, Checler F. Alpha-secretase-derived product of beta-amyloid precursor protein is decreased by presenilin 1 mutations linked to familial Alzheimer's disease. *J Neurochem* 1997;69(6):2494–9.
- [3] Barone FC, Clark RK, Feuerstein G, Lenkinski RE, Sarkar SK. Quantitative comparison of magnetic resonance imaging (MRI) and histologic analyses of focal ischemic damage in the rat. *Brain Res Bull* 1991;26(2):285–91.
- [4] Benveniste H, Blackband S. MR microscopy and high resolution small animal MRI: applications in neuroscience research. *Prog Neurobiol* 2002;67(5):393–420.
- [5] Benzi G, Moretti A. Are reactive oxygen species involved in Alzheimer's disease? *Neurobiol Aging* 1995;16(4):661–74.
- [6] Borchelt DR, Ratovitski T, van Lare J, Lee MK, Gonzales V, Jenkins NA, et al. Accelerated amyloid deposition in the brains of transgenic mice coexpressing mutant presenilin 1 and amyloid precursor proteins. *Neuron* 1997;19(4):939–45.
- [7] de Bustos F, Molina JA, Jimenez-Jimenez FJ, Garcia-Redondo A, Gomez-Escalonilla C, Porta-Etessam J, et al. Serum levels of coenzyme Q10 in patients with Alzheimer's disease. *J Neural Transm* 2000;107(2):233–9.
- [8] Ernster L, Dallner G. Biochemical, physiological and medical aspects of ubiquinone function. *Biochim Biophys Acta* 1995;1271(1):195–204.
- [9] Esiri MM, Nagy Z, Smith MZ, Barnetson L, Smith AD. Cerebrovascular disease and threshold for dementia in the early stages of Alzheimer's disease. *Lancet* 1999;354(9182):919–20.
- [10] Evans DA, Funkenstein HH, Albert MS, Scherr PA, Cook NR, Chown MJ, et al. Prevalence of Alzheimer's disease in a community population of older persons. Higher than previously reported. *JAMA* 1989;262(18):2551–6.
- [11] Ferrante RJ, Andreassen OA, Dedeoglu A, Ferrante KL, Jenkins BG, Hersch SM, et al. Therapeutic effects of coenzyme Q10 and remacemide in transgenic mouse models of Huntington's disease. *J Neurosci* 2002;22(5):1592–9.
- [12] Gainotti G, Acciarri A, Bizzarro A, Marra C, Masullo C, Misciagna S, et al. The role of brain infarcts and hippocampal atrophy in subcortical ischaemic vascular dementia. *Neurol Sci* 2004;25(4):192–7.
- [13] Grieb P, Ryba MS, Sawicki J, Chrapusta SJ. Oral coenzyme Q10 administration prevents the development of ischemic brain lesions in a rabbit model of symptomatic vasospasm. *Acta Neuropathol (Berl)* 1997;94(4):363–8.
- [14] Hattori K, Lee H, Hum PD, Crain BJ, Traystman RJ, DeVries AC. Cognitive deficits after focal cerebral ischemia in mice. *Stroke* 2000;31(8):1939–44.
- [15] Hebert LE, Beckett LA, Scherr PA, Evans DA. Annual incidence of Alzheimer disease in the United States projected to the years 2000 through 2050. *Alzheimer Dis Assoc Disord* 2001;15(4):169–73.
- [16] Iadecola C, Gorelick PB. Converging pathogenic mechanisms in vascular and neurodegenerative dementia. *Stroke* 2003;34(2):335–7.
- [17] Jack Jr CR, Shiung MM, Weigand SD, O'Brien PC, Gunter JL, Boeve BF, et al. Brain atrophy rates predict subsequent clinical conversion in normal elderly and amnesic MCI. *Neurology* 2005;65(8):1227–31.
- [18] Jellinger KA. Understanding the pathology of vascular cognitive impairment. *J Neurol Sci* 2005;229–230:57–63.
- [19] Jellinger KA, Attems J. Prevalence and pathogenic role of cerebrovascular lesions in Alzheimer disease. *J Neurol Sci* 2005;229–230:37–41.
- [20] Katzman R. Alzheimer's disease. *N Engl J Med* 1986;314(15):964–73.
- [21] Lee SP, Falangola MF, Nixon RA, Duff K, Helpert JA. Visualization of beta-amyloid plaques in a transgenic mouse model of Alzheimer's

- disease using MR microscopy without contrast reagents. *Magn Reson Med* 2004;52(3):538–44.
- [22] Li H, Klein G, Sun P, Buchan AM. CoQ10 fails to protect brain against focal and global ischemia in rats. *Brain Res* 2000;877(1):7–11.
- [23] Likeman M, Anderson VM, Stevens JM, Waldman AD, Godbolt AK, Frost C, et al. Visual assessment of atrophy on magnetic resonance imaging in the diagnosis of pathologically confirmed young-onset dementias. *Arch Neurol* 2005;62(9):1410–5.
- [24] Matthews RT, Yang L, Browne S, Baik M, Beal MF. Coenzyme Q10 administration increases brain mitochondrial concentrations and exerts neuroprotective effects. *Proc Natl Acad Sci USA* 1998;95(15):8892–7.
- [25] Mattson MP. Cellular actions of beta-amyloid precursor protein and its soluble and fibrillogenic derivatives. *Physiol Rev* 1997;77(4):1081–132.
- [26] Maurer I, Zierz S, Moller HJ. A selective defect of cytochrome c oxidase is present in brain of Alzheimer disease patients. *Neurobiol Aging* 2000;21(3):455–62.
- [27] Monfort JC. A population-based study of dementia in 85-year-olds. *N Engl J Med* 1993;329(1):63–4.
- [28] Ostrowski RP. Effect of coenzyme Q10 (CoQ10) on superoxide dismutase activity in ET-1 and ET-3 experimental models of cerebral ischemia in the rat. *Folia Neuropathol* 1999;37(4):247–51.
- [29] Ostrowski RP. Effect of coenzyme Q(10) on biochemical and morphological changes in experimental ischemia in the rat brain. *Brain Res Bull* 2000;53(4):399–407.
- [30] Parker Jr WD, Parks J, Filley CM, Kleinschmidt-DeMasters BK. Electron transport chain defects in Alzheimer's disease brain. *Neurology* 1994;44(6):1090–6.
- [31] Qin L, Liu Y, Cooper C, Liu B, Wilson B, Hong JS. Microglia enhance beta-amyloid peptide-induced toxicity in cortical and mesencephalic neurons by producing reactive oxygen species. *J Neurochem* 2002;83(4):973–83.
- [32] Schroeter M, Jander S, Stoll G. Non-invasive induction of focal cerebral ischemia in mice by photothrombosis of cortical microvessels: characterization of inflammatory responses. *J Neurosci Methods* 2002;117(1):43–9.
- [33] Shults CW, Flint Beal M, Song D, Fontaine D. Pilot trial of high dosages of coenzyme Q10 in patients with Parkinson's disease. *Exp Neurol* 2004;188(2):491–4.
- [34] Shults CW, Haas R, Oakes D, Kieburtz K, Plumb S, Shoulson I, et al. Measuring the effects of therapy in Parkinson disease. *JAMA* 2004;291(20):2430–1 (author reply 1).
- [35] Shults CW, Haas RH, Passov D, Beal MF. Coenzyme Q10 levels correlate with the activities of complexes I and II/III in mitochondria from parkinsonian and nonparkinsonian subjects. *Ann Neurol* 1997;42(2):261–4.
- [36] Shults CW, Oakes D, Kieburtz K, Beal MF, Haas R, Plumb S, et al. Effects of coenzyme Q10 in early Parkinson disease: evidence of slowing of the functional decline. *Arch Neurol* 2002;59(10):1541–50.
- [37] Snowdon DA, Greiner LH, Mortimer JA, Riley KP, Greiner PA, Markesbery WR. Brain infarction and the clinical expression of Alzheimer disease. The Nun Study. *JAMA* 1997;277(10):813–7.
- [38] Sohmiya M, Tanaka M, Tak NW, Yanagisawa M, Tanino Y, Suzuki Y, et al. Redox status of plasma coenzyme Q10 indicates elevated systemic oxidative stress in Parkinson's disease. *J Neurol Sci* 2004;223(2):161–6.
- [39] Tsukahara Y, Wakatsuki A, Okatani Y. Antioxidant role of endogenous coenzyme Q against the ischemia and reperfusion-induced lipid peroxidation in fetal rat brain. *Acta Obstet Gynecol Scand* 1999;78(8):669–74.
- [40] Veitch K, Hombroecx A, Caucheteux D, Pouleur H, Hue L. Global ischaemia induces a biphasic response of the mitochondrial respiratory chain. Anoxic pre-perfusion protects against ischaemic damage. *Biochem J* 1992;281(3):709–15.
- [41] Warner DS, Sheng H, Batinic-Haberle I. Oxidants, antioxidants and the ischemic brain. *J Exp Biol* 2004;207(18):3221–31.
- [42] Watson BD, Dietrich WD, Busto R, Wachtel MS, Ginsberg MD. Induction of reproducible brain infarction by photochemically initiated thrombosis. *Ann Neurol* 1985;17(5):497–504.
- [43] Zekry D, Duyckaerts C, Moulins R, Belmin J, Geoffre C, Herrmann F, et al. Degenerative and vascular lesions of the brain have synergistic effects in dementia of the elderly. *Acta Neuropathol (Berl)* 2002;103(5):481–7.
- [44] Zhang F, Eckman C, Younkin S, Hsiao KK, Iadecola C. Increased susceptibility to ischemic brain damage in transgenic mice over-expressing the amyloid precursor protein. *J Neurosci* 1997;17(20):7655–61.