

Coenzyme Q10 Reduces β -Amyloid Plaque in an APP/PS1 Transgenic Mouse Model of Alzheimer's Disease

Xifei Yang · George Dai · Geng Li · Edward S. Yang

Received: 1 July 2009 / Accepted: 23 September 2009
© Humana Press 2009

Abstract We previously reported that coenzyme Q10 (CoQ10) could reduce intracellular deposition in an aged transgenic mouse model. Here, we further tested the effect of CoQ10 on amyloid plaque in an amyloid precursor protein/presenilin 1 transgenic mouse model of Alzheimer's disease (AD). By using immunohistochemistry and magnetic resonance imaging to determine the burden of amyloid plaque, we found that oral administration of CoQ10 can efficiently reduce the burden of the plaques in this mouse model. These data demonstrate that in addition to reducing intracellular deposition of A β , CoQ10 can also reduce plaque pathology. Our study further supports the use of CoQ10 as a therapeutic candidate for AD.

Keywords Alzheimer's disease · Coenzyme Q10 · A β · Plaque · MR imaging

X. Yang · G. Li (✉) · E. S. Yang
Hong Kong Applied Science and Technology Research Institute
Company Limited,
Hong Kong, China
e-mail: ligenggeng@gmail.com

X. Yang
Department of Pathophysiology, Tongji Medical College,
Huazhong University of Science and Technology,
Wuhan, China

G. Dai
Athinoula A. Martinos Center of Biomedical Imaging,
Department of Radiology, Massachusetts General Hospital,
Boston, MA, USA

Introduction

Alzheimer's disease (AD) is the most common neurodegenerative disease characterized by extracellular deposition of senile plaques consisting of beta-amyloid (A β) peptide. Most studies indicate that plaques have toxic effects and mediate the downstream pathological changes and cognitive impairment observed in AD (Carpenter et al. 1993; Paulson et al. 2008; Chen et al. 2008). Thus, preventing and reducing plaque is a therapeutic strategy in the treatment of AD.

Coenzyme Q10 (CoQ10) is an endogenous powerful antioxidant that buffers the potential adverse consequences of free radicals produced during oxidative phosphorylation in the inner mitochondrial membrane (Young et al. 2007). Oxidative stress has been shown to be involved in the pathogenesis of many neurodegenerative diseases, including AD and Parkinson's disease (PD) and Huntington's disease (HD). CoQ10 has been found to have protective effects against PD and HD (Bhat and Weiner 2005; Beal and Shults 2003). In a recent study, we have reported that CoQ10 could reduce intracellular deposition of A β , which is believed to be an early event in the pathogenesis of AD (LaFerla et al. 2007), in an aged transgenic mouse model only exhibiting intracellular deposition of A β (Yang et al. 2008). However, the effect of CoQ10 on extracellular deposition of amyloid plaque, one of the two pathological hallmarks of AD, was not explored.

In this study, we investigated the effect of CoQ10 on plaque by using an amyloid precursor protein (APP)/presenilin 1 (PS1) mouse model of AD with widespread plaque pathology.

Materials and Methods

Antibodies and Chemicals

Polyclonal primary antibodies specific for A β peptides ending at residue 40 (A β 1–40) and A β peptides ending at residue 42 (A β 1–42) were obtained from Biosource International (Camarillo, CA, USA) and Chemicon International (Temecula, CA, USA), respectively. The detection kit (Histostain-SP) for immunohistochemistry was obtained from ZEMED (South San Francisco, CA, USA).

Animals and Treatment

All animal experiments were performed according to the National Institutes of Health Guide for the Care and Use of Laboratory animals (NIH Publication no. 8023, revised 1978), and all efforts were made to minimize animal suffering and to reduce the number of animals used. Fourteen to 15 and half-month-old male animals were divided into two groups: control ($n=5$) and treatment group ($n=4$). The mice were fed standard pelleted mouse chow. In the control groups, mice were given the same dosage of pure vegetable oil as that of the CoQ10 (Purina Test Diets, Richmond, IN, USA) via gavage for 60 days. The treated mice were given CoQ10 (1,200 mg/kg/day, Tishcon/Gel-Tec) via gavage for 60 days. During the treatment, the food consumed per gram of mouse weight was stable (data not shown). The dosage of CoQ10 was referenced to our previous report (Li et al. 2007).

Immunohistochemistry

Immunohistochemistry for light microscopy was performed using routine protocols (Celis 1994). In brief, mice were deeply anesthetized and transcardially perfused with 100 ml 0.01 M PBS, pH 7.4, first and then 100 ml 4% paraformaldehyde solution. The brain was dissected out and postfixed in the same 4% paraformaldehyde solution for 3–4 h and then placed in phosphate-buffered 30% sucrose overnight. On the following day, 30- μ m frozen sections were coronally cut on a sliding microtome (AO Scientific Instruments, USA). Immunohistochemical staining was performed following the procedure as described (Wu 1996; Sun et al. 2003). Briefly, free-floating sections were blocked with 0.3% H₂O₂ in absolute methanol for 10 min, and nonspecific sites were blocked with instant goat serum for 30 min at room temperature. Sections were then incubated 24–48 h at 4°C with the primary antibodies (1:500 for A β 1–40 and 1:1,000 for A β 1–42). The slides were developed by biotinylated secondary antibodies (1:200) and avidin peroxidase conjugate (1:200)/diaminobenzidine tetrachloride (0.05%) system.

MR Imaging

Magnetic resonance (MR) imaging was performed on a Bruker AV 500 Wide Bore NMR spectrometer (11.7 T, 500 MHz ¹H frequency) with the Bruker Microimaging accessory at Bruker BioSpin Corp., Billerica, MA, USA. The RF coil is a 20-mm-diameter resonator of birdcage type. The resonator is part of the Micro2.5AHS probe body with the Micro2.5 gradient set using the Great 60 gradient amplifiers (maximum gradient of 1,500 mT/m at 60 Amps). Parameters for 3D RARE sagittal brain images were TE=6.644 ms, effective echo time=40.34, TR=2,000 ms, number of averages=12, rare factor=12, total scan time=18 h, FOV=16 \times 12 \times 12 mm, spatial resolution=0.100 \times 0.067 \times 0.067 mm/pixel, matrix size=160 \times 180 \times 180, and slice thickness 12 mm.

Image Analysis

After MR imaging, the mouse brains were sectioned coronally at 30 μ m using a sliding microtome. The sections were collected serially. For image analysis of immunohistochemistry and MR imaging, three coronal sections taken from anterior (bregma, –1.34 mm), middle (bregma, –1.82 mm), and posterior hippocampus (bregma, –2.54 mm) of each mice were analyzed. All immunoreactive areas of plaque were quantitatively analyzed using Image Pro Plus 4.5 (Media Cybernetics Inc., Silver Spring, MD, USA). Data are expressed by area of cortex and hippocampus occupied by the positive immunoreactivity.

Statistical Analysis

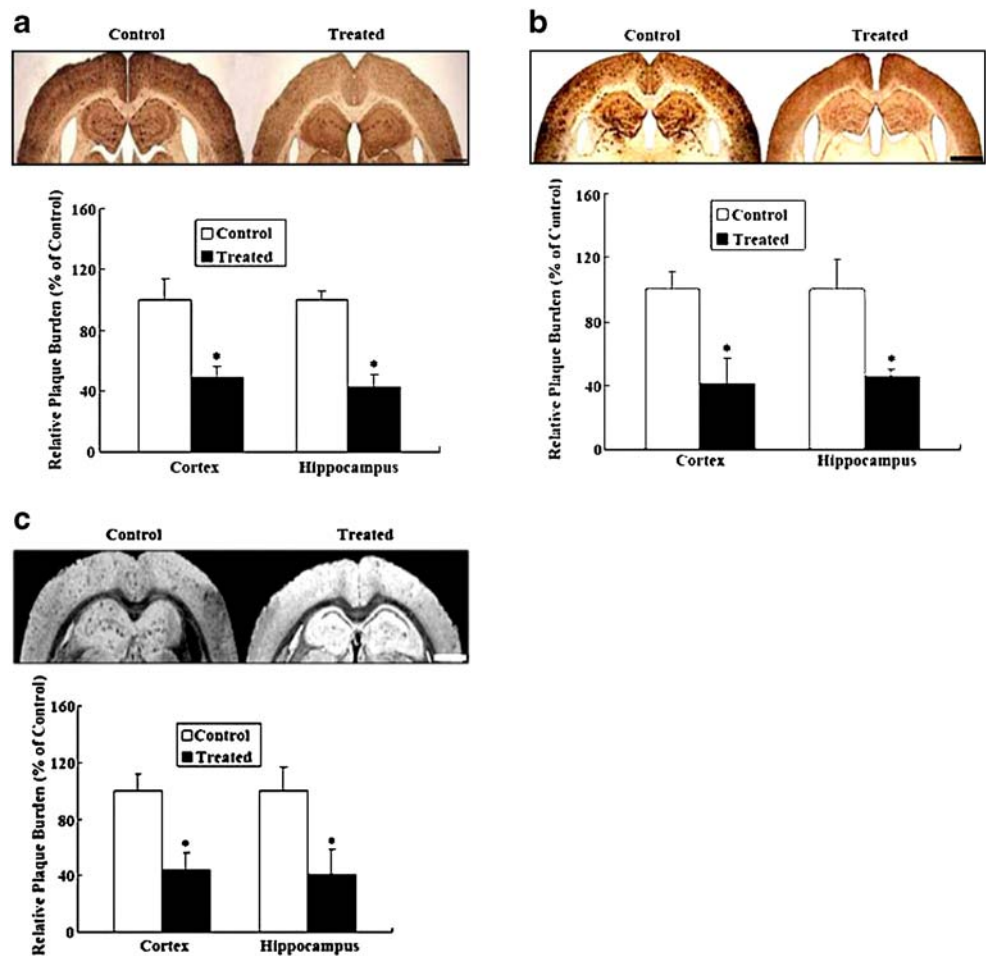
Data were expressed as mean \pm standard deviation and analyzed using a statistical program SigmaStat (Jandel Scientific, Chicago, IL, USA). Student's *t* test was used to determine the different means among groups. Statistical significance was set at $p<0.05$.

Results

CoQ10 reduces amyloid plaque in cortex and hippocampus of APP/PS1 transgenic mice.

In order to test the effects of CoQ10 on amyloid plaques in cortex and hippocampus of APP/PS1 transgenic mice, immunohistochemistry of A β 1–40 deposits (Fig. 1a), immunohistochemistry of A β 1–42 deposits (Fig. 1b), and MR imaging (Fig. 1c) were performed. The immunoreactive area of A β 1–40 in cortex and hippocampus of CoQ10-treated mice was decreased by 51.8% (48.2 \pm 8.2 vs. 100 \pm 13.6, $p=0.003$) and 57.7% (42.3 \pm 8.8 vs. 100 \pm 5.5,

Figure 1 The effects of oral treatment with CoQ10 on the plaque in cortex and hippocampus of APP/PS1 transgenic mice. The burden of plaques in cortex and hippocampus of APP/PS1 transgenic mice treated with CoQ10 was analyzed by immunohistochemistry of A β 1–40 deposits (a), immunohistochemistry of A β 1–42 deposits (b), and MR imaging (c), respectively ($n=3-4$ /group), $*p<0.05$. Scale bar=100 μ m



$p=0.0004$) compared with that of control diet group, respectively (Fig. 1a). The immunoreactive area of A β 1–42 in cortex and hippocampus of CoQ10-treated mice was decreased by 58.7% (41.3 ± 15.9 vs. 100 ± 11.8 , $p=0.004$) and 54.2% (45.8 ± 4.2 vs. 100 ± 18.7 , $p=0.0044$) compared with that of control diet group, respectively (Fig. 1b). In order to explore a potential application of MR imaging in analysis of plaque pathology, the image of plaques in the transgenic mouse model was obtained by high-field MRI scanning and the plaque were quantitatively analyzed, which were done as described by Jack et al. (2005). Plaque quantitative analysis was repeated three times for the purpose of precision. The average value of three repeated measures was obtained in each animal. High-field imaging showed that CoQ10-treated mice exhibited significantly decreased deposition of plaque compared to the control diet group (Fig. 1c). The positive area of plaque in cortex and hippocampus of CoQ10-treated mice was decreased by 56.1% (43.9 ± 12.3 vs. 100 ± 11.2 , $p=0.0042$) and 59.2% (40.8 ± 17.9 vs. 100 ± 16.5 , $p=0.0094$) compared with that of control diet group, respectively (Fig. 1c).

Discussion

In the present study, by using immunohistochemistry and high-field MR imaging analysis, we found that oral administration of CoQ10 can efficiently reduce plaque pathology in an APP/PS1 transgenic mouse model.

Accumulating lines of evidence demonstrate that mitochondrial dysfunction and oxidative damage may play a role in the pathogenesis of neurodegenerative diseases including AD and PD. CoQ10 serves as an important cofactor of the electron transport chain and also serves as an important antioxidant in both mitochondria and lipid membranes (Beyer 1992). A clinical study reported that CoQ10 can slow disease progression in patients with early-stage PD (Shults et al. 2002). The animal studies also showed that CoQ10 can exert neuroprotective effects against in PD by reducing oxidative stress and improve energy dysfunction (see review Beal 2004). Due to similar pathomechanism of PD to AD, CoQ10 is indicative of being also effective in the treatment of AD. Our previous study has demonstrated that CoQ10 can reduce intracellular

deposit of A β , a pathological event early in the pathogenesis of AD. In this study, by using the aged APP/PS1 transgenic mice exhibiting widespread extracellular plaque deposition, we found that CoQ10 also exerted neuroprotective effects against extracellular plaque pathology. These data suggest that CoQ10 could be also an effective treatment for AD in a relatively late stage of AD as well as in early stage. The protective effects of CoQ10 may derive from its antioxidant effect. The precise molecular mechanisms underlying the neuroprotective effects of CoQ10 remain to be elucidated in future studies.

Previously, it was reported that amyloid plaques can be detected by high-field MR imaging in vitro (Benveniste et al. 1999). In order to further validate the potential efficiency of MR imaging in tracking amyloid plaque change, we tested by using MR imaging the change of plaques in the APP/PS1 transgenic mouse model with and without the treatment of CoQ10. The data from MR imaging analysis were in agreement with those from immunohistochemistry. This study supports the potential application of high-field MR imaging to in vivo amyloid plaque study in future studies.

In summary, our data show that CoQ10 can significantly reduce plaque pathology in the APP/PS1 mouse model for AD. It is indicated that CoQ10 might be a therapeutic candidate for the treatment of AD.

Acknowledgment This study was supported by a grant from Rejuvenis, Hong Kong Jockey Club Charities Trust.

References

- Beal MF (2004) Mitochondrial dysfunction and oxidative damage in Alzheimer's and Parkinson's diseases and coenzyme Q10 as a potential treatment. *J Bioenerg Biomembr* 36:381–386
- Beal MF, Shults CW (2003) Effects of coenzyme Q10 in Huntington's disease and early Parkinson's disease. *Biofactors* 18:153–161
- Benveniste H, Einstein G, Kim KR et al (1999) Detection of neuritic plaques in Alzheimer's disease by magnetic resonance microscopy. *Proc Natl Acad Sci U S A* 96:14079–14084
- Beyer RE (1992) An analysis of the role of coenzyme Q in free radical generation and as an antioxidant. *Biochem Cell Biol* 70:390–403
- Bhat V, Weiner WJ (2005) Parkinson's disease. Diagnosis and the initiation of therapy. *Minerva Med* 96:145–154
- Carpenter MK, Crutcher KA, Kater SB (1993) An analysis of the effects of Alzheimer's plaques on living neurons. *Neurobiol Aging* 14:207–215
- Celis JE (1994) Cell biology—a laboratory handbook. Academic, San Diego
- Chen G, Chen KS, Knox J et al (2008) A learning deficit related to age and beta-amyloid plaques in a mouse model of Alzheimer's disease. *Nature* 408:975–979
- Jack CR Jr, Wengenack TM, Reyes DA et al (2005) In vivo magnetic resonance microimaging of individual amyloid plaques in Alzheimer's transgenic mice. *J Neurosci* 25:10041–10048
- LaFerla FM, Green KN, Oddo S (2007) Intracellular amyloid-beta in Alzheimer's disease. *Nat Rev Neurosci* 8:499–509
- Li G, Zou L, Jack CR Jr et al (2007) Neuroprotective effect of coenzyme Q10 on ischemic hemisphere in aged mice with mutations in the amyloid precursor protein. *Neurobiol Aging* 28:877–882
- Paulson JB, Ramsden M, Forster C et al (2008) Amyloid plaque and neurofibrillary tangle pathology in a regulatable mouse model of Alzheimer's disease. *Am J Pathol* 173:762–772
- Shults CW, Oakes D, Kieburtz K et al (2002) Effects of coenzyme Q10 in early Parkinson disease: evidence of slowing of the functional decline. *Arch Neurol* 59:1541–1550
- Sun L, Liu SY, Zhou XW et al (2003) Inhibition of protein phosphatase 2A- and protein phosphatase 1-induced tau hyperphosphorylation and impairment of spatial memory retention in rats. *Neuroscience* 118:1175–1182
- Wu W (1996) Potential roles of gene expression change in adult rat spinal motoneurons following axonal injury: a comparison among c-jun, off-affinity nerve growth factor receptor (LNGFR), and nitric oxide synthase (NOS). *Exp Neurol* 141:190–200
- Yang X, Yang Y, Li G et al (2008) Coenzyme Q10 attenuates beta-amyloid pathology in the aged transgenic mice with Alzheimer presenilin 1 mutation. *J Mol Neurosci* 34:165–171
- Young AJ, Johnson S, Steffens DC et al (2007) Coenzyme Q10: a review of its promise as a neuroprotectant. *CNS Spectr* 12:62–68